

## PREVENTION OF PARACETAMOL TOXICITY IN BROILER CHICKS WITH A HERBAL MIXTURE

\*SAVITA MARMAT<sup>a1</sup> AND H. S. RATHORE<sup>b</sup>

<sup>ab</sup>School of Studies in Zoology and Biotechnology, Vikram University, Ujjain M.P., India

### ABSTRACT

Fourteen days old broiler chicks were pretreated orally with a mixture of six herbal products *Terminalia chebula*, *Glycyrrhiza glabra*, *Curcuma longa*, *Triphala*, *Asparagus racemosus* and *Ocimum sanctum* at three doses levels (group IV, V and VI) for seven days and on 7<sup>th</sup> day all chicks received single sublethal dose of acetaminophen (paracetamol) via i.m injection at (LD<sub>5</sub>). Controls (Gr-I) received only distilled water and one injection of vehicle. Only drug treated chicks were also maintained (Gr-II). One group (Gr-III) received only distilled water and received single i.m. injection of paracetamol at LD<sub>5</sub>. Chicks were sacrificed on 9<sup>th</sup> day to obtain blood and tissues for hematological, histological and biochemical observations. Paracetamol declined hemoglobin content, damaged RBC, caused anemia and increased serum levels of bilirubin, GOT (glutamic-oxaloacetic transaminase), GPT (glutamic-pyruvic transaminase), alkaline phosphatase, urea and creatinine indicating hepatorenal tissue injury. Early degenerative changes could be detected in liver, kidney, spleen, left ventricular wall, lungs and proventriculus. Pretreatment with lowest dose of herbal mixture remained ineffective but medium and highest doses could fully prevented toxic effects of paracetamol. *In-vitro* of testing herbal mixture is found to possess antioxidative activity. Pretreatment with highest dose of herbal mixture enhanced hepatic GSH content than control (Gr-II) and even maintained normal (control) like levels following paracetamol challenge in all groups. Probable protective role played by herbal mixture against paracetamol toxicity based on its antioxidant principles, minerals and vitamins is discussed.

**KEYWORDS:** Paracetamol toxicity, Chick, Herbals, Target, Non target organs

Toxicity of acetaminophen (paracetamol) and its prevention with herbal compound is extensively studied in human and in mammalian models (Sharma et al., 2008; Makwana et al., 2012). During recent past veterinary use of diclofenac is banned due to threat of extinction of vultures hence paracetamol appeared safe alternative (MoEF 2006, Swan et al., 2006). Limited studies have been conducted to know toxicity of paracetamol in poultry and its prevention with herbals (Lindenthal et al., 1993. Kumar et al., 2009; Rangnathan et al., 2013). Recently studies on the toxicity of paracetamol at lethal dose report towards target and non target organs of broiler chicks have been conducted and published (Marmat et al. 2015, Marmat and Rathore 2015 a,b, Marmat and Rathore a, b 2016). Present study was planned to find out potential of a herbal mixture against sublethal toxicity of paracetamol on target and non target organs in broiler chicks under experimental conditions.

### MATERIALS AND METHODS

#### Animal

One day old, healthy, unsexed broiler chicks (*Gallus gallus*

*domesticus*) were obtained from Government poultry farm (M.P. Rajya Pashu Dhan Evam Kukkut Vikas Nigam, Bhopal). Chicks were acclimatized for 13 days in animal house of the department and were maintained on prepared food i.e grinded wheat, corn, soyabean and gram in equal quantity i.e (1:1:1:1 wt/wt) and 10% per kg crushed prawns. and water ad-libitum. At 14th day average body weight of chick was about 250±20 gms. During winter and rainy seasons temperature was maintained by keeping on a 200 wt bulbs for 12 hrs.

#### Herbal Mixture

Herbal mixture consisted of six herbal products: *Terminalia chebula* (Harar, dried fruit- myrobalan), *Glycyrrhiza glabra* (Mulethi, dried roots), *Curcuma longa* (Haldi, dried rhizome), *Triphala* (dried powdered nuts in 1:1:1 ratio wt/wt of three nuts *T. chebula*, *T. bellerica*, *P. emblica*), *Asparagus racemosus* (Shatavari, dried roots), *Ocimum sanctum* (Tulsi, dried leaves). Herbals were procured from recognized local shop. Selected components of each herbal drug were crushed in an electrical grinder to get fine powder.

<sup>1</sup>Corresponding author

**Doses of Herbal Mixture**

Based on human dose of each herb described in ayurvedic literature and on mice (Makwana et al, 2012) a herbal mixture was prepared which consisted of *Triphala*-22.22%, *A. racemosus*-22.22%, *T.chebula*-22.22%, *O. sanctum*-11.11%, *G. glabra*-11.11%, *C. longa*-11.11%. This mixture is used at three doses level i.e 100 mg/kg/bw (highest dose), 75 mg/kg/bw (medium dose) and 50 mg/kg/bw (lowest dose). For chick of 250 gm body weight three doses were calculated and thoroughly mixed with distilled water using mortar and pestle which was filter by ordinary filter paper. This clear aqueous filtrate was orally administered to chicks using blunt, bent, thick (no. 18) needle fitted on a syringe. Doses were administered at fix time i.e during 12:30-1:30 noon.

**Chemicals**

Paracetamol injections i.e Fibrinil IM manufactured by NLS Silmour HP were used for IM administration. It contained 150 mg paracetamol/ml in 2% v/v Benzyl alcohol and water qs. Benzyl alcohol: CDH, Delhi was used. In this study sublethal dose (LD5=350 mg/kg/bw) of paracetamol is administered based on lethal dose (Marmat et al, 2015).

**Ethical Aspects**

Chicks were handled gently, however, there is no ban on the use of chicks for experimental studies. This fact is in the knowledge of departmental and university authorities.

**Experimental Design**

As shown below

**Histological and Histopathological Observations**

On 9th day, 48 hours after paracetamol administration chloroform anaesthised chicks were dissected to take out their organs for measurements and subsequent fixation in alcoholic Bouin's fluid for histology. Sectioned material (5µ) was processed for routine haematoxylin and eosine staining. Slides were observed under compound microscope (Ajay Optic, India, IS-4381) and were photographed under trinocular image capture microscope (Novel Optics, India, NV-18). Pathological changes were judged and confirmed. (Bischoff and Motoko, 2012)

**Hematological Observations**

A drop of fresh blood was taken out from left ventricle of heart and was placed on a slide with the help of syringe and spread out. Dried smears were fixed in absolute alcohol for thirty seconds and stored. Afterwards, slides were stained with ready to use crystal violet (CDH-Delhi).

*In-vitro* Testing: Antioxidant activity of herbal mixture extract (0.25 to 2.00 mg/ml) was determined by DPPH free radical scavenging methods (Blois, 1958; Gulcin et al, 2005; Elmastas et al, 2006) at MRD Life Sciences Pvt. Ltd., Lucknow (U.P.)

Hepatic GSH contents were determined by spectrophotometric estimation methods (Ellman, 1959; Sapakal et al, 2008) at Pinnacle Biomedical Research centre, Bhopal (M.P.).

Group I	Control group: Chicks were pretreated orally with distilled water daily for 7 days followed by single i.m. administration of vehicle (Benzyl alcohol) 2 hr after last treatment (vol. equal to that of paracetamol used) on 7th day in group III.
Group II	Only drug treated group: Chicks were administered highest dose of herbal mixture for 7 days.
Group III	Paracetamol treated group: Initially chicks were given distilled water orally for 7 days and one sub lethal dose (LD5=350 mg/kg/bw)of paracetamol was administrated i.m on 7th day, 2 hr after last treatment.
Group IV, V, VI	Paracetamol challenge to drug pretreated groups: Chicks were pre treated with herbal mixture in distilled water at three doses (HD:100, MD:75 and LD:50 mg/kg/bw) orally daily for 7 days followed by one paracetamol i.m administration on 7th day, 2 hr after last treatment.

(HD=Highest Dose, MD=Medium Dose, LD=Lower Dose)

### Biochemical Observations

On 9th day 48 hours after paracetamol administration, blood sample of each chick was taken out directly from heart under mild chloroform. Biochemical parameters like serum GOT (glutamic-oxaloacetic transaminase), GPT (glutamic-pyruvic transaminase), bilirubin and alkaline phosphatase as liver function tests and creatinine and urea as kidney function tests were estimated using standard ready to use available kits made by standard companies (BEACON Diagnostics Pvt. Ltd, Gujrat; ERBA diagnostics and Mannheim GmbH, Germany; AGAPPE Diagnostics Ltd., Kolkata) in a pathology laboratory.

### Statistical Analysis

All statistically comparisons were made by Student's t-test. Experiments were done thrice and number of observations was six. Only consistent data are considered.

## RESULTS

Results of the present study are presented in the tables (1 to 4) and photomicrographs (1-42) in seven plates. These are self explanatory hence for brevity findings are not described in detail. Herbal mixture alone exerted positive health effects as it enhanced and maintained hepatic GSH content in various groups of chicks. Paracetamol caused anemia, damaged RBC and disturbed histophysiology of other target organs (liver, kidney) and non target organs (spleen, heart, lungs and proventriculus). No changes could be observed in the morphology i.e shape, size and volume of spleen in any group. Pretreatment with herbal mixture at lowest dose remained ineffective but two higher doses could enabled chicks to combat against paracetamol challenge. In *in-vitro* testing of herbal mixture is found to be of antioxidant nature.

## DISCUSSION

Results of the present study revealed two facts that herbal mixture alone has not adversely affected on the contrary it has exerted beneficial effects in broiler chicks. Another important finding is an encouraging one as seven days pretreatment with herbal mixture at two higher doses

enabled chicks to combat against paracetamol challenged. Both issues are discussed under following headings:

### Toxicity of Paracetamol

Paracetamol-induced hematological effects like anemia, destruction of RBC and darkening of blood (methemoglobinemia) and damaged spleen are on record in mammalian model and in birds (Hjelle and Grauer, 1986; Daniel, 1995, Bakhiet and Mohammad, 2008, Emadi et al, 2015, Marmat and Rathore, 2015 a). Toxic metabolite of paracetamol i.e NAPQI (N-acetyl-benzoquinineimine) causes oxidative stress at cellular level which damages membranes, proteins, nucleic acid and thiol groups of enzymes and hemoglobin (Koop, 1992, Suhail and Ahmad, 1995; Bottomley and Eberhard, 1998; Lahouel et al, 2004 ). Avian mitochondria are reported to be functional in RBC and to play role in antioxidant defence (Steir et al, 2013). Mitochondria could be damaged due to toxic action of peroxynitrite which is formed following paracetamol toxicity (Cover et al, 2005). Inhibition of both, DNA synthesis and its repair by paracetamol is on record (Insel, 1996), hence affected RBC and spleen is not an unexpected finding in the present one.

Limited studies have been conducted on extrahepatic toxicity of paracetamol in mice, rats and human (Baudouin et al, 1995, Mehrpour et al, 2011, Micheli et al, 1994; Ohtani et al, 1989; Placke et al, 1987, Sanerkin, 1971, Will and Tomkins, 1971). This effect was considered as direct damaging effect of paracetamol following depletion of GSH (glutathione) level in liver and other tissues (Micheli et al, 1994). Few reports do exist on paracetamol induced damages in liver, kidney, heart, lung, intestine, proventriculus and brain in avian model at cellular levels in the range of 20 to 20,000 mg/kg/bw following single or repeated exposures (Bhar et al, 2005, Bakhiet and Mohammad, 2008, Kumar et al, 2009, Hedau and Bhandarkar, 2010, Rangnathan et al., 2013. Marmat and Rathore 2015 a,b, Marmat and Rathore 2016 a,b).

Unfortunately there exists only one report which describes that paracetamol induced liver damage was associated with decreased GSH content and increased lipid peroxidation in broiler chick (Bhar et al., 2005). Paracetamol induced hyperacidity and ulcers in rats and humans (Rainsford and Whitehouse, 2006) as well as

hyperplasia and degeneration of villi in broiler chicks is on record (Jayakumar et al., 2010). In rats paracetamol-induced epithelial hyperplasia of non glandular mucosa of stomach is reported (McKee and Gass, 2011). Such ill effect of paracetamol was attributed to be due to endocrine disturbances (Albert et al, 2013). It seems logical to accept established fact that oxidative stress is responsible for the observed toxicity of paracetamol in broiler chicks in the present case.

#### **Explanation for preventive role played by herbal mixture against paracetamol**

Oral administration of *C. longa* powder to three days old vencob chicken for 42 days decreased serum uric acid and albumin and increased total serum protein, globulin and haemoglobin but no changes could be detected in alkaline phosphatase, transaminases and calcium. Also, significant rise in the levels of Mg, Zn, Fe and Cu could be noticed. Better growth and feed consumption could be noticed. According authors (Kumari et al., 2007) micronutrient content of *C. longa* and overall biological effect was responsible for observed beneficial effect. Added *C. longa* powder in the food of broiler chicks caused significant higher growth rate i.e body weight and organ weight (Durrani et al, 2006), while it increased hemoglobin content and hemocrit but no other parameter of blood (Isroli et al, 2011). Supplementation of *C. longa* rhizome powder for 21 days enhanced LDH (lactate dehydrogenase) and AST (aspartate transaminase) and declined ALT (alanine transaminase) and ALP (alkaline phosphatase) indicating positive effect on hepatic tissue in broiler chicks (Emadi and Kermanshai, 2007). In a report addition of *C. longa* powder in the diet of broilers resulted in higher body weight and feed conversion ratio without affecting hematological parameters (Raghdad, 2012). *C. longa* rhizome powder supplementation in the feed of broiler chicks enhanced antioxidant enzymes SOD (superoxide dismutase), LPO (lipid peroxidation), CAT (catalase) and immunity in comparison to controls (Sethy et al, 2017).

Dietary administration of *O. sanctum* to one day old broiler chicks, leaf powder alone at 0.25 and 0.50% feed enhanced SOD and Catalase activities but addition of selenium also increased SOD and GSH-Px in the serum. Authors suggested that addition of *Ocimum sanctum* leaf

powder and 0.3 ppm selenium enabled broiler chicks to overcome oxidative stress (Reddy et al, 2009). *O. sanctum* leaf extract addition in the drinking water of one day old broiler chicks gained more body weight than controls at five weeks. It altered TEC, ESR, PCV but Hb% remained unaffected (Hasan et al, 2016). Addition of 1% *A. racemosus* root powder in the food of broiler chicks resulted in better body growth performance and alterations in the hematological parameters, serum protein, albumin and globulin levels (Rekhate et al., 2010). An antistress activity of *P. emblica* and *C. longa* supplementation in food of broiler chick is reported because hematological parameters remained unaffected during stressful seasonal changes (Singh et al., 2008). A mixture of *P. emblica*, *O. sanctum* and *T. chebula* is found to be antistressor in one day old broiler chicks at one kg/ton of food against heat exposure. Parameters of study were glutathione reductase and superoxide dismutase (Sujatha et al, 2010). Stress hormones i.e cortisol and thyroxine (T4) were declined.

Presence of minerals (Fe, Cu, Zn, Na, K, Ca, Mn, Cr, Ni, V) are reported in the components of herbal mixture used in present study (Samudralwar and Garg, 1996. Lalla et al., 2004. Narendhirakannan et al., 2005. Kumari et al., 2007. Singh et al., 2011. Seal, 2011. Imelouane et al, 2011. Shafqutullah et al., 2013, Alok et al., 2013). These micronutrients can be held responsible for maintaining optimum level to prevent anemia and other ill effects of paracetamol as many of these are required for chicks (NRC, 1984). In the present study herbal mixture alone increased hepatic GSH content than controls and even maintained normal level after paracetamol challenge. This finding can be explained because vitamins like C, E and beta carotene and amino acid precursors of GSH tripeptide i.e Cystine, Glycine and Glutamic acid are present in the components of herbal mixture (Hathway, 1956. Akram et al., 2010. Singh et al., 2011. Said et al., 2012, Debnath et al., 2011. Shafqutullah et al, 2013. Presence of many compounds having antioxidant activity like tannins, flavonoids, terpenoids, saponins, anthraquinone, gallic acid, glycosides, triterpenoids, polyphenols, alkaloids, steroids are also reported in the components of herbal mixture used (Debnath et al., 2011. Shafqutullah et al., 2013. Sharma et al., 2013, Chattopadhyay and Bhattacharya, 2007. Seal,

2011, Alok et al., 2013, Akram et al. 2010). Herbal mixture used in the present study is found to exert an antioxidant activity *in-vitro*. Individually all six herbal components of mixture have been reported to be antioxidant in-vitro (Hakkim et al., 2007. Hazra et al, 2010. Hossain et al., 2012; Said et al., 2012; Sahu and Saxena, 2014. Karhan et al., 2016). Due to strong antioxidant principles in the herbal mixture chicks could overcome paracetamol toxicity.

Infact broiler chicks need a number of nutrients in their food for their optimum growth and physiological activities (NRC, 1984). It is felt that components of herbal mixture contained many nutrients which might be lacking in the prepared food supplied to chicks. Due to this reason

prior administration of herbal mixture could make chicks healthier in terms of having better antioxidant potential which enabled them to combat against paracetamol challenge.

It is concluded that under laboratory conditions tested herbal mixture is found to prevent sublethal toxicity of paracetamol in broiler chicks due to antioxidative principles, minerals and vitamins present in its constituents.

**ACKNOWLEDGEMENTS**

Authors thank Government of India for supporting this study in the form of Rajiv Gandhi National Fellowship to first author. We also thank MRD Life Sciences, Lucknow

**Table 1: Hematological parameters in broiler chicks pretreated with herbal mixture and subsequently challenged with a sublethal dose (LD<sub>5</sub>) of paracetamol. (Mean±SEM)**

S. No.	Groups	Parameters						
		Hb%	TRBC (M/uL)	PCV%	MCV(fm)	MCH (pg)	MCHC (g/dL)	RDW (fL)
1	Group I (Controls)	12.86±0.30	4.63±0.19	37.63±0.08	114.40±1.03	37.45±0.08	34.03±0.06	10.53±0.08
2	Group II (Only Drug) % Change	12.66±0.47 1.55% NS	4.71±0.08 1.72% NS	37.41±0.09 0.58% NS	112.67±1.04 1.51% NS	37.25±0.07 0.53% NS	34.01±0.08 0.96% NS	10.36±0.06 1.61% NS
3	Group III (Paracetamol treated) % Change	9.23 a ±0.31 28.22%↓	2.78 a ±0.13 39.95%↓	42.71 a ±0.06 13.49%↑	146.77 a ±1.22 28.29%↑	42.44 a ±0.04 13.32%↑	28.82 a ±0.05 15.31%↓	12.90 a ±0.05 22.50%↑
4	Group IV (Lowest Dose pre-treated) % Change	9.37 a ±0.33 27.13%↓	3.16 a ±0.12 31.74%↓	41.86 a ±0.05 11.24%↑	141.89 a ±1.65 24.02%↑	41.10 a ±0.05 9.74%↑	29.23 a ±0.07 14.10%↓	12.70 a ±0.04 20.60%↑
5	Group V (Medium Dose pre-treated) % change	12.70±0.48 1.24% NS	4.40 ±0.15 2.80% NS	37.86 ±0.10 0.61% NS	113.70 ±0.98 0.61% NS	37.21 ±0.11 0.64% NS	33.95 ±0.06 0.23% NS	10.75 8±0.09 2.08% NS
6	Group VI (Highest Dose pre-treated) % change	12.65 ±0.26 1.63% NS	4.56 ±0.09 1.51% NS	37.51 ±0.07 0.31% NS	113.27 ±0.94 0.98% NS	37.19 ±0.09 0.69% NS	33.98 ±0.08 0.14% NS	10.66 ±0.05 1.23% NS

\*Statistically significant based on Student's t-test at 5% level of significance (n=6, p<2.201).

↑=Significant Increase, ↓=Significant Decrease. 'a' = Group I vs all groups, NS = Non Significant.

Key: Hb%: Hemoglobin%, TRBC: Red Blood Cell, PCV: Packed Cell Volume, MCV: Mean Corpuscular Volume, MCH: Mean Corpuscular Hemoglobin, MCHC: Mean Corpuscular Hemoglobin Concentration, RDW: Red Cell Distribution Width.

**Table 2: Liver and Kidney function tests in broiler chicks pretreated with herbal mixture and subsequently challenged with a sublethal dose (LD5) of paracetamol. (Mean±SEM)**

S. No.	Groups Treatments	Liver Function Tests				Kidney Function Tests	
		Total Bilirubin (mgms%)	SGPT (U/L)	SGOT (U/L)	S. Alkaline. Phosphatase (IU/L)	B. Urea (mgms%)	S. Creatinine (mgms%)
1	Group I (Controls)	0.29±0.019	140.70±1.66	665±1.42	4405±3.38	12.76±0.51	0.85±0.04
2	Group II (Only Drug)	0.27±0.017 NS	141.11±1.72 NS	662±1.46 NS	4411±3.41 NS	12.56±0.22 NS	0.86±0.05 NS
3	Group III (Paracetamol treated)	0.39 <sup>a</sup> ±0.001 34.48%↑	161.12 a ±1.28 14.51%↑	864 a ±1.77 29.92%↑	5100 a ±3.37 15.77%↑	20.12 a ±0.77 57.68%↑	1.10 a ±0.087 29.41%↑
4	Group IV (Lowest Dose pretreated)	0.37 <sup>a</sup> ±0.002 27.58%↑	158.17 a ±1.18 12.41%↑	825 a ±1.81 24.06%↑	4990 a ±3.66 13.28%↑	18.00 a ±0.41 41.0%↑	1.05 a ±0.078 23.5%↑
5	Group V (Medium Dose pretreated)	0.28±0.013 NS	140.53 ±1.54 NS	663 ±1.62 NS	4410 ±3.87 NS	12.43 ±0.56 NS	0.84 ±0.066 NS
6	Group VI (Highest Dose pretreated)	0.30 ±0.011 NS	140.67 ±1.62 NS	661 ±1.65 NS	4415±3.45 NS	12.51 ±0.48 NS	0.86 ±0.062 NS

\*Statistically significant based on Student's t-test at 5% level of significance (n=6, p<2.201).

↑=Significant Increase, 'a' = Group I vs all groups, NS = Non Significant

**Table 3: Hepatic GSH (mmol/gm) content in various groups of broiler chicks (Mean±SEM)**

S. No.	Groups	Mean±SEM
1	Control (Untreated)	0.712±0.0084
2	Only drug treated & vehicle administrated	0.789±0.0097* 10.81%↑
3	Single sublethal paracetamol administration (i.m)	0.662±0.0111* 7.02%↓
4	Pretreated with lowest dose of herbal mixture and challenged with paracetamol	0.714±0.0103 NS
5	Pretreated with medium dose of herbal mixture and challenged with paracetamol	0.710±0.0138 NS
6	Pretreated with highest dose of herbal mixture and challenged with paracetamol	0.716±0.0113 NS

\*Statistically significant based on Student's t-test at 5% level of significance (n=6, p<2.201).

↑=Significant Increase, ↓=Significant Decrease, NS=Non Significant.



**Table 4: Anti oxidant activity of herbal mixture using DPPH free radical scavenging method in term of percentage inhibition of free radicals (Mean ± SD )**

Entry	Concentration (mg/ml)	Sample 1	Ascorbic Acid	BHT
01	0.25	34.0 ± 1.81	12.56 ± 0.28	19.72 ± 1.46
02	0.50	53.4 ± 2.72	24.31 ± 1.34	43.31 ± 1.01
03	1.00	82.85 ± 1.35	42.81 ± 0.59	55.74 ± 1.73
04	2.00	90.5 ± 0.22	93.40 ± 0.15	75.88 ± 0.86

(BHT= Butylated hydroxytoluene)

**Plate- I, Fig. 1-6 : Morphology of RBC in Broiler chicks (Crystal Violet 450X)**

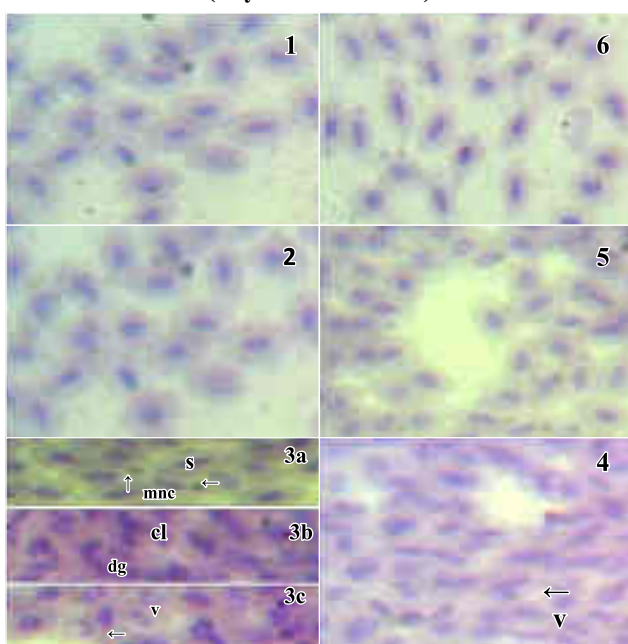


Fig.1 Showing normal shape of RBC with distinct nuclei and no sign of pathology in control. Fig. 2 only herbal mixture pretreated group showing normal morphology of RBC. Fig. 3a Paracetamol treated group shows swollen RBC (s) and micronuclei (mnc), 3b shows clumps (cl) of RBC and early degeneration (dg) of nuclei, 3c shows vacuolization (v) in the nuclear region of RBC. Fig. 4 Shows mild damage towards RBC of chicks which were pre treated with lowest dose of herbal mixture and subsequently challenged with paracetamol. Only nuclear vacuolization (v) is evident but micronuclei are at all not seen i.e better morphology is seen in comparison to earlier figure. Fig. 5 and 6: Showing quite usual i.e normal morphology of chick RBC as seen in controls Fig. 1 pretreated with medium and highest doses of herbal mixture and challenge with paracetamol.

**Plate- II, Fig. 1-6 : Histology of Spleen in Broiler Chick (HE100X)**

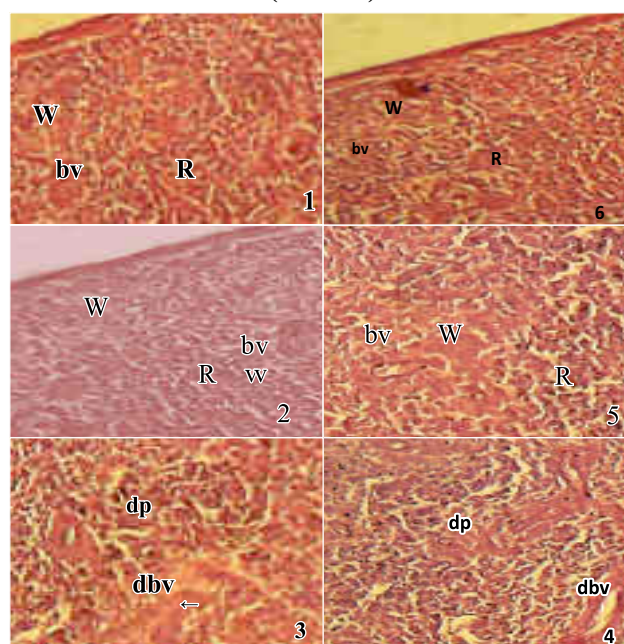


Fig.1 and 2 Showing normal histology of spleen in control and only herbal mixture pretreated chicks with well organized red pulp (R) and white pulp (W) with normal blood vessel (bv). Fig. 3 Paracetamol treated showing mild disorganization (dp) of both red and white pulps and damaged blood vessel (dbv). Fig. 4 Lowest dose pretreated with herbal mixture showing less disorganization (dp) and less affected blood vessel (dbv) i.e better situation in comparison to earlier figure Fig. 3, Fig. 5 and 6 Medium and highest doses pretreated and subsequently paracetamol administered chicks showing usual, normal, well organized pulps in their spleens.

**Plate-III, Fig. 1-6 :Histology of Liver in Broiler Chick (HE, 100X, Inset 450X)**

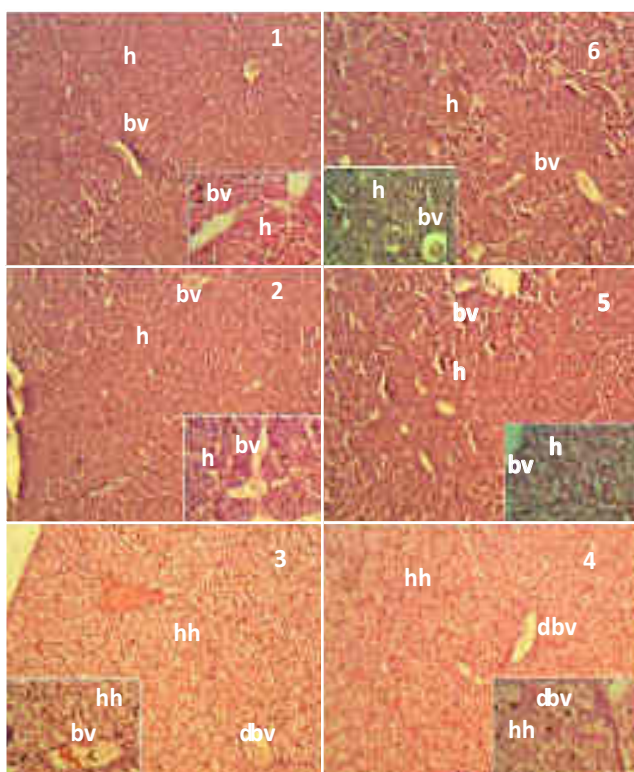


Fig. 1 and 2: Showing normal histology of control and only herbal mixture pretreated liver sections with well organized hepatocytes (h) around blood vessels (bv). Fig-3: Paracetamol treated showing hypertrophy i.e hypertrophied hepatocytes (hh) around damaged blood vessels (dbv). Fig. 4: Lowest dose pretreated showing no improvement hence appears like earlier figure. Fig-5 and 6: Medium and highest doses pretreated showing normal structure of liver sections.

**Plate-IV, Fig. 1-6 : Histology of Kidney in Broiler Chick (HE, 100X, Inset 450X)**

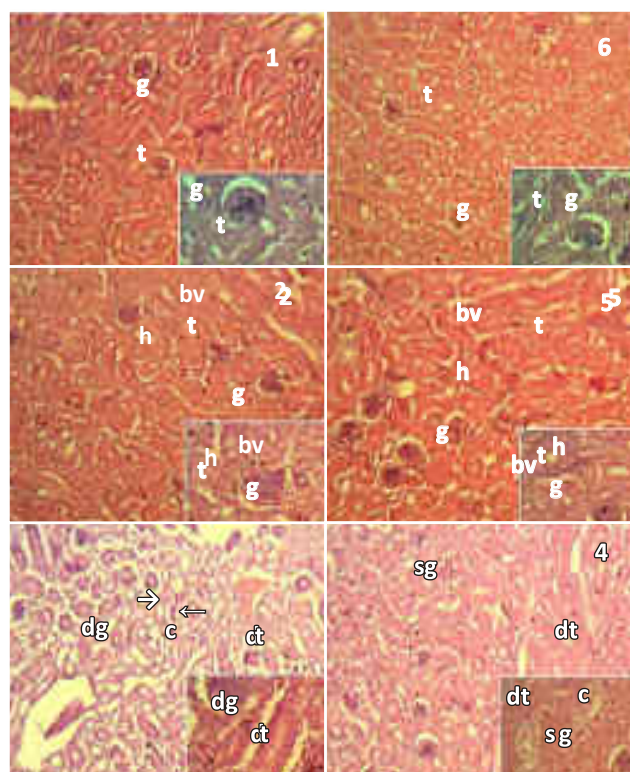


Fig-1 and 2: Showing normal histology of control and only with herbal mixture pretreated kidney sections with well organized glomeruli (g) and tubules (t). Fig-3 Paracetamol treated showing cast formation (c= dying tubules), disorganization of tubules (dt) and disintegrating glomeruli (dg). Fig-4 Lowest dose pretreated and subsequently sublethal paracetamol challenged show mild disorganization of tubules (dt) is seen as cast formation is not seen but few shrunken glomeruli (sg) seen at some places. Better situation is seen as compared to earlier figure. Fig-5 and 6 Pretreated with medium and highest doses of herbal mixture followed by paracetamol challenge showing normal structures of glomeruli and tubules.



Plate-V, Fig. 1-6 : Histology of Lung in Broiler Chick (HE, 100X; Inset 450X)

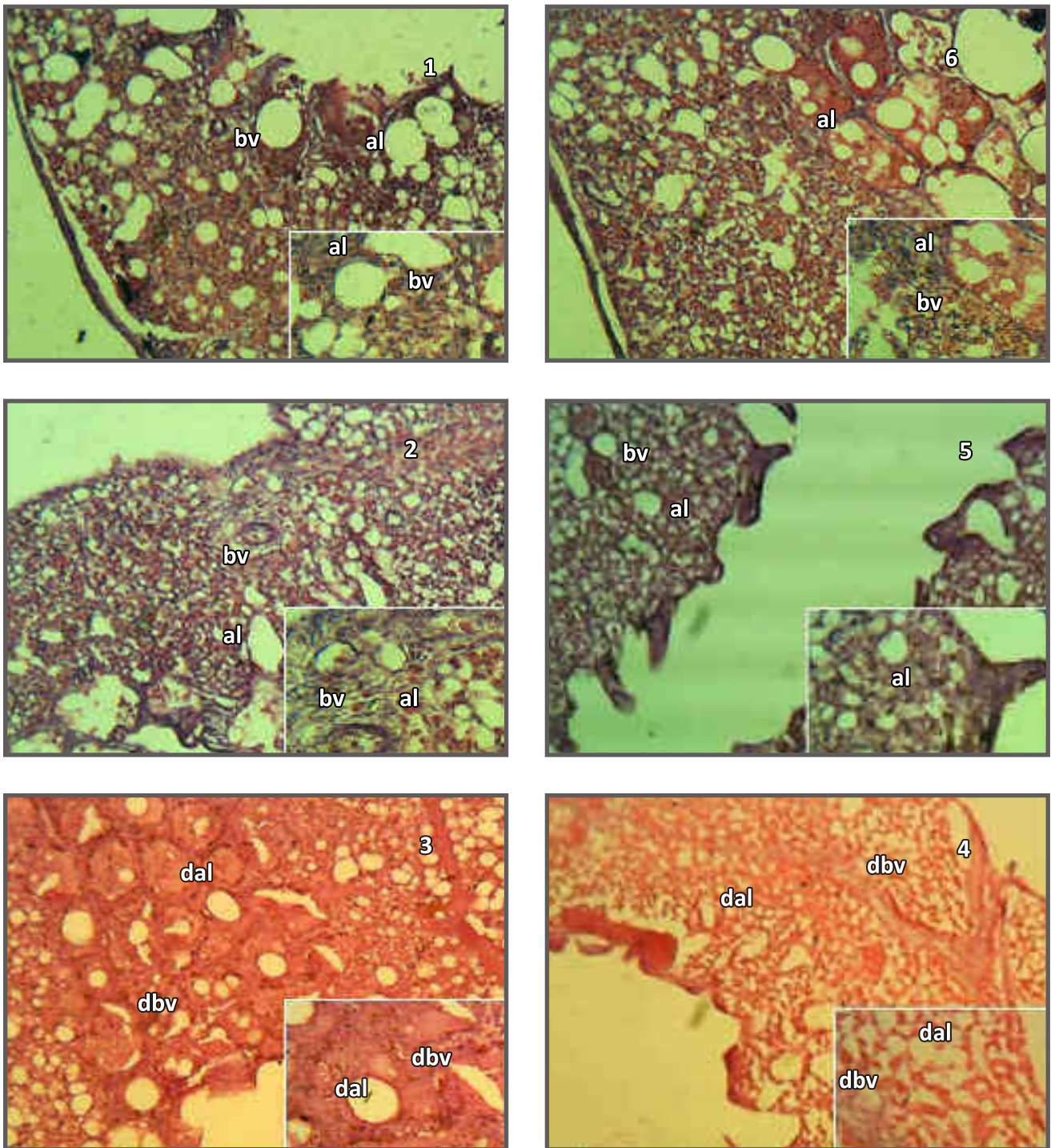


Fig-1 and 2: Showing normal histology of control and only herbal mixture pretreated lung sections with well organized blood vessel (bv) and alveoli (al). Fig-3: Paracetamol treated showing disorganization of alveoli (dal) and blood vessel (dbv) are seen. Fig-4: Lowest dose pretreated showing disorganization. Fig-5 and 6: Pretreated with medium and highest doses showing normal histology in lung section like controls.



Plate-VI, Fig. 1-6 : Histology of Left ventricle in Broiler Chick (HE, 100X)

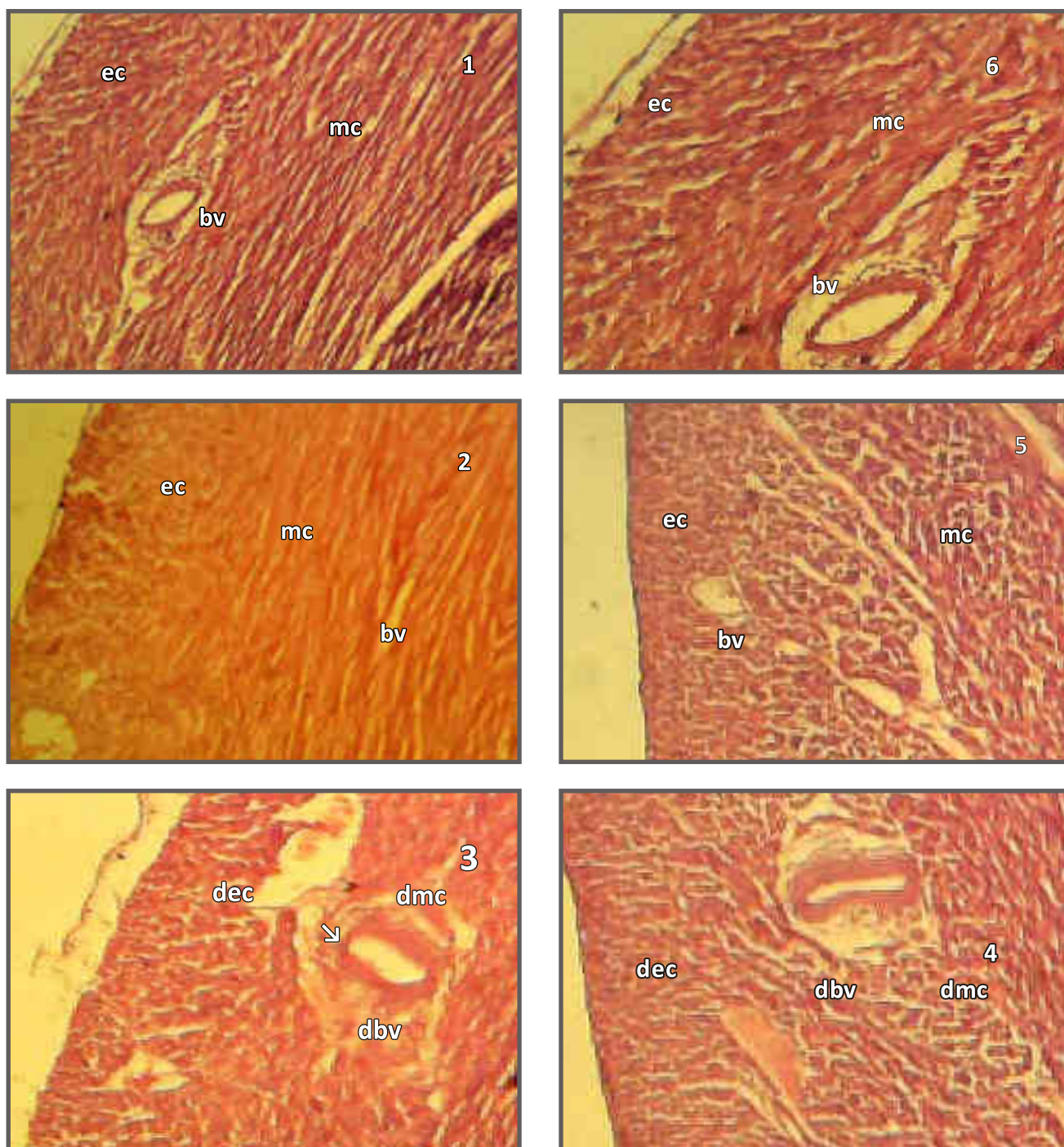


Fig-1 and 2: Showing normal histology of control and only herbal mixture treated heart sections with well organized epicardium (ec), myocardium (mc) and blood vessel (bv). Fig-3 Paracetamol caused mild disorganization of both epicardium (dec) and myocardium (dmc), which is showing early degenerative changes around blood vessels (dbv). Fig-4 Lowest dose pretreated showing less disorganization Fig-5 and 6: Medium and highest doses pretreatments showing control like normal histology.

Plate VII, Fig. 1-6 : Histology of Proventriculus in Broiler Chick (HE, 100X) and Inset (450X)

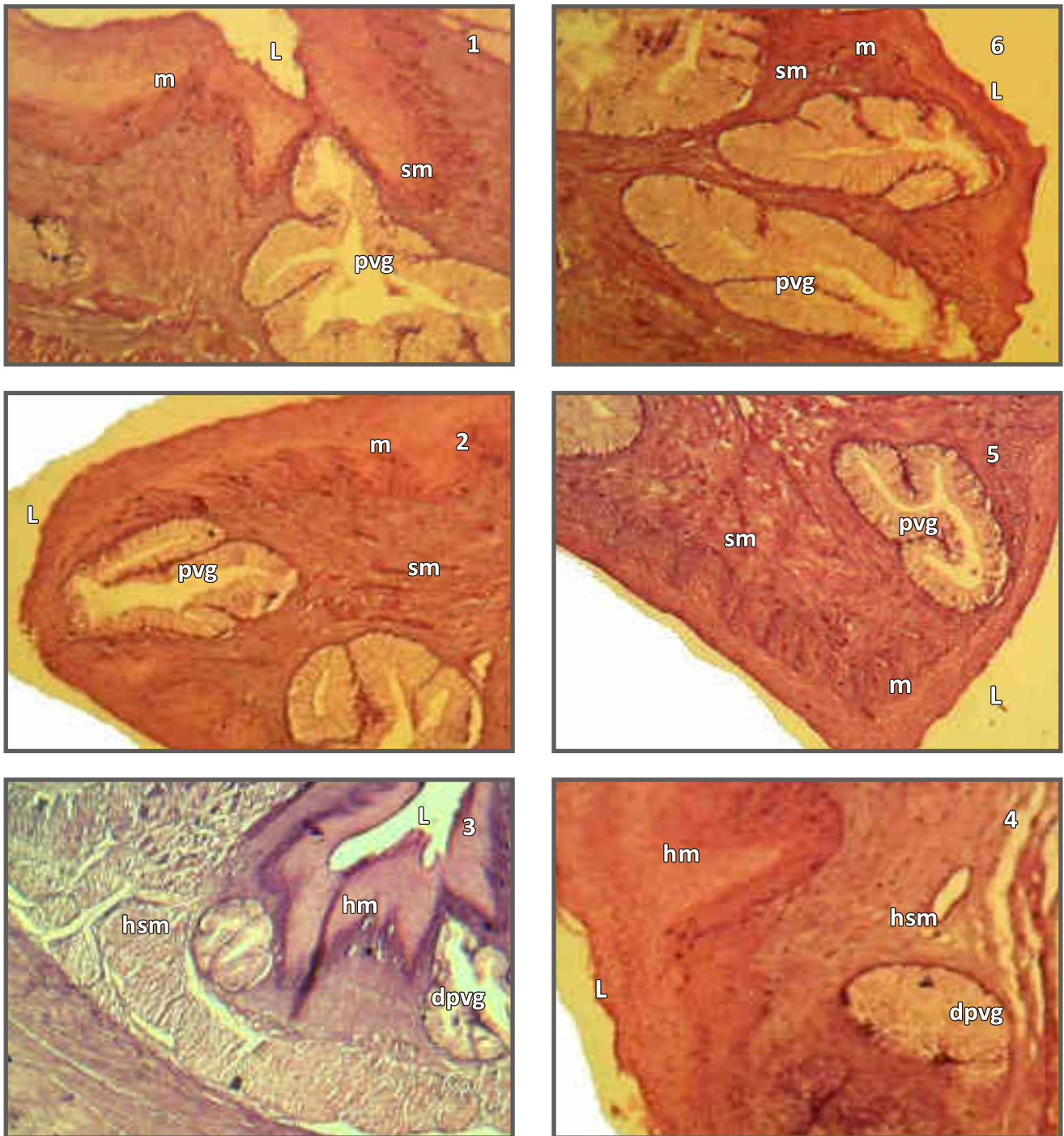


Fig-1 and 2: Showing normal histology of control and only herbal mixture pretreated proventriculus sections with well organized proventricular glands (pvg) in submucosa (sm) and mucosa (m) enclosing lumen (L). Fig-3: Paracetamol caused degeneration of proventricular gland (dpvg) and hyperplasia of mucosa (hm) and hyperplastic submucosa (hsm). Fig-4: Pretreatment with lowest dose of herbal mixture and subsequent paracetamol challenge could not prevent toxicity of paracetamol challenge as still damage is seen like earlier figure 3. Fig-5 and 6: Control like normal architecture is seen due to pretreatment with medium and highest doses of herbal mixture.



## REFERENCES

- Akram M., Shahab-uddin, Ahmed A., Khan S., Hannan A., E-Mohiuddin and Asif M., 2010. *Curcuma longa* and *Curcumin*: A review article. Rom. J. Biol.-Plant Biol., 55(2):65-70.
- Albert O., Desdoits L.C., Lesne L., Legrand A., Guille F., Bensalah k., Dejuq-Rainsford N. and Jegou B., 2013. Paracetamol, aspirin and indomethacin display endocrine disrupting properties in the adult human testis in vitro. Hum Reprod, 28(7):1890-1898.
- Alok S., Jain S.K., Verma A., Kumar M., Mahor A. and Sabharwal M., 2013. Plant profile, phytochemistry and pharmacology of *Asparagus racemosus* (Shatavari): A review. Asian Pac. J. Trop. Dis., 3(3):242-251.
- Bakhiet A.O. and Mohammad A., 2008. Response of bovans-hybrid chicks to *Allium cepa*, paracetamol or their mixture. Sud. J.Vet. Sci. Anim. Husb., 47:1-2.
- Baudouin, Simon V., Howdle P., Grady J. and Webster N.R.; 1995. Acute lung injury in fulminant hepatic failure following paracetamol poisoning. Thorax. 50: 399-402.
- Bhar M.K., Das S.K., Chakraborty A.K., Mandal T.K. and Roy S.; 2005. Hepatoprotective effect of Enliv® on paracetamol-induced liver damage in broiler chicks. Int J Pharmacol, 37(4):257-258.
- Bischoff and Mukai Motoko.; 2012. Chapter-28. Toxicity of over the counter drugs in Veterinary Toxicology: Basic and Clinical Principles by Gupta Ramesh C, IInd Edn. 361-390, California, USA.
- Blois M.S., 1958. Antioxidant determinations by the use of a stable free radical. Nature. 29:1199-1200.
- Bottomley S.S. and Muller-Eberhard V.; 1998. Pathophysiology of the heme synthesis. Pemin Hematol, 25:282-303.
- Chattopadhyay R. R. and Bhattacharya S. K., 2007. Herbal spices as alternative antimicrobial food preservatives: An update. Pharmacognosy Reviews, 1:239-247.
- Cover C., Mansouri A., Knight T.R., Bajt M.L., Lemastars J.J., Pessayre D. and Jaeschke H., 2005. Peroxynitrite-induced mitochondrial and endonuclease-mediated nuclear DNA damage in acetaminophen hepatotoxicity. J Pharmacol Exp Ther, 315:879-887.
- Daniel P.S., 1995. Methemoglobinemia and anemia in a dog with acetaminophen toxicity. Can Vet J, 36:515-517.
- Debnath J., Prakash T., Karki R., Kotresha D. and Sharma P.; 2011. An experimental evaluation of anti-stress effects of *Terminalia chebula*. J. Physiol. Biomed Sci., 24(2):13-19.
- Durrani F.R., Ismail M., Sultan A., Suhail S.M., Chand N. and Durrani Z., 2006. Effect of different levels of feed added turmeric (*Curcuma longa*) on the performance of broiler chicks. Journal of Agricultural and Biological Science, 1(2):9-11.
- Ellman G.L.; 1959 Tissue Sulfhydryl Groups, Archives of Biochemistry and Biophysics 82:70-77.
- Elmastas M., Gulcin I., Beydemir S., Kufrevioglu O.I. and Aboul- Enein H.; 2006. A study on the in vitro antioxidant activity of Juniper (*Juniperus communis* L.) seeds extracts. Anal Lett, 39:47-65.
- Emadi M. and Kermanshahi H., 2007. Effect of turmeric rhizome powder on the activity of some blood enzymes in broiler chickens. Int J Poult Sci., 6:48-51.
- Emadi M., Hadavi A., Ameri J. and Kermanshahi H.; 2015. The effect of *curcumin* on acetaminophen-induced toxicity on performance and some blood parameters of Japanese Quail from 0-37 days of age. Iranian Journal of Applied Animal Science, 5(1):203-207.
- Gulcin I., Beydemir S., Sat I.G. and Kufrevioglu O.I.; 2005. Evaluation of antioxidant activity of Cornelian Cherry (*Cornus mas* L.). Acta Aliment Hung, 34:193-202.
- Hakkim FL, Shankar CG, Girija S., 2007. Chemical composition and antioxidant property of Holy Basil (*Ocimum sanctum* L.) Leaves stems and Inflorescence and their in vitro callus cultures. Journal of Agricultural and Food Chemistry. 55(22):9109:9117.
- Hasan M.N., Mostofa M., Sorwar M.G., Hasan M.T., Das K. and Hossain D.M.N., 2016. Effects of tulsi leaf extract on body weight gain in broiler production. Bangl J Vet. Med., 14(1):21-25.



- Hathway D.E.; 1956. Amino acids, Fruit acids and Polyols of Myrobalans. *Biochem. J.*, **63**(3):380-7.
- Hazra B, Sarkar R, Biswas S, Mandal N., 2010. Comparative study of the antioxidant and reactive oxygen species scavenging properties in the extracts of the fruit of *Terminalia chebula*, *Terminalia bellerica* and *Embllica officianalis*. *BMC Complementary and Alternative Medicine*. **10**:20.
- Hedau M. and Bhandarkar A.G., 2010. Histopathological changes in experimental paracetamol toxicity in poultry. *Royal Veterinary Journal of India*, **6**(1):23-25.
- Hjelle J.J. and Grauer G.F., 1986. Acetaminophen-induced toxicosis in dogs and cats. *J Am Vet Med Assoc*, **188**:742-746.
- Hossain MI, Sharmin FA, Akhter S, Bhuiyan MA, Shahriar M., 2012. Investigation of cytotoxicity and *in-vitro* antioxidant activity of *Asparagus racemosus* root extract. *International Current Pharmaceutical Journal*. **1**(9):250-257.
- Imelouane B., Tahri M., Elbastrioui M., Aouinti F. and Elbachiri A., 2011. Mineral contents of some medicinal and aromatic plants growing in Eastern Morocco. *J. Mater. Environ. Sci.*, **2**(2):104-111.
- Insel P.A., 1996. The pharmacological basis of therapeutics. 9th Edn. New York: McGraaw Hill Internation, Texas, 617.
- Isroli S., Widiastuti E. and Prabowo NS.; 2011. Effect of turmeric extract on blood parameters, feed efficiency and abdominal fat content in broilers. *J. Indonesian Trop. Anim. Agric.*, **36**(1):21-26.
- Jayakumar K., Mohan K., Narayana swamy H.D., Shridhar N.B. and Bayer M.D., 2010. Study of nephrotoxic potential of acetaminophen in birds. *Toxicol Int*, **17**(2):86-89.
- Karhan F, Avsar C, Ozyigit IIO, Berber I, 2016. Antimicrobial and antioxidant activities of medicinal plant *Glycyrrhiza glabra* var. *glandulifera* from different habitats. *Biotechnology & Biotechnological equipments*. **30**(4): 797-804.
- Koop D.R., 1992. Oxidative and reductive metabolism by Cytochrome P450 2E1. *FASEB J*, **6**:724-730.
- Kumar P., Prasad R., Singh K.K. and Roy B.K., 2009. Hepatoprotective effect of *Centella asiatica* against paracetamol induced liver damage in broiler chicken. *Indian Journal of Poultry Science*, **44**(1):101-104.
- Kumari P., Gupta M.K., Ranjan R., Singh K.K. and Yadava R., 2007. *Curcuma longa* as feed additive in broiler birds and its patho-physiological effects. *Indian J. Exp. Biol.*, **45**:272-277.
- Lahouel M., Ouadi O. and Khiari N., 2004. Effects hepatic et hematologique du paracetamol. *Saidal info*, **7**:60-66.
- Lalla J.K., Hamrapurkar P.D. and Mamanian H.M., 2004. Mineral content and microbial impurity of *Triphala churna* and its raw materials. *Indian J Traditional Knowledge*, **3**(1):86-91.
- Lindenthal J., Sinclair J.F., Howell S., Cargill I., Sinclair P.R. and Tailor T., 1993. Toxicity of paracetamol in cultured chick hepatocytes treated with methotrexate. *Eur J Pharmacol*, **228** (5-6):289-298.
- Makwana M., Sharma A. and Rathore, H.S., 2012. Shall herbs combat hepatorenal toxicity of paracetamol? Lambert Academic Publishing Co. Germany.
- Marmat S., Qureshi Taj N. and Rathore H.S., 2015. Lethal doses of acetaminophen (Paracetamol) for young broiler chicks. *Indian Journal of Pharmaceutical Science & Research*, **5**(1):23-26.
- Marmat S. and Rathore H.S.; 2015a, Lethal doses of paracetamol (Acetaminophen) damages blood and spleen in broiler chick. *International Journal of Pharmacology & Toxicology*, **5**(3): 157-162.
- Marmat S. and Rathore H.S.; 2015b. Hepatorenal toxicity of paracetamol (acetaminophen) in broiler chicks at lethal dose. *Indian Journal of Applied & Pure Biology*, **30**(2):117-122.
- Marmat S. and Rathore H.S., 2016a. Paracetamol (acetaminophen) induced Cardio-Pulmonary damage in Broiler Chicks. *Journal of Advanced Zoology*, **37**(1):9-13.
- Marmat S. and Rathore H.S., 2016b. Acetaminophen-induced proventricular damage in broiler chick. *International Journal of Pharmacy & Therapeutics*, **7**(3):97-100.
- McKee J.S. and Gass J.H., 2011. Acetaminophen-induced

- forestomach lesion in normal rats following intravenous exposure. *Toxicologic Pathology*, **39**:861-866.
- Mehrpour O., Afshari R., Delshad P., Jalalzadeh M., and Khodashenas M., 2011. Cardiotoxicity due to paracetamol overdose- A case study and review of the literature. *Indian Journal of Forensic Medicine & Toxicology*, **5**(2):31.
- Micheli L., Cerretani D., Fiaschi A.I., Giorgi G., Romeo M.R. and Runci, F.M., 1994. Effect of acetaminophen on glutathione levels in rat testis and lung. *Environ Health Perspectives*, **102**(9): 63-64.
- MoEF (Ministry of Environment and Forests), 2006. Proceedings of the International Conference on Vulture Conservation, New Delhi, Government of India.
- Narendhirakannan R.T., Subramanian S. and Kandaswamy M., 2005. Mineral content of some medicinal plants used in the treatment of diabetes mellitus. *Biological Trace Element Research*, **103**:109-115.
- National Research Council (NRC); 1984: National requirements of poultry. National Academy of Sciences, USA.
- Ohtani, N., Matsuzaki M., Anno Y., Ogawa H., Matsuda, Y. and Kusukawa R.; 1989. A case of myocardial damage following acute paracetamol poisoning. *Jpn Circ J.*, **53**(3):278-82.
- Placke M.E., Wyand D.S. and Cohen S.D., 1987. Extrahepatic lesions induced by acetaminophen in the mouse. *Toxicologic Pathology*, **15**(4):381-387.
- Rainsford K.D and Whitehouse M.W., 2006. Paracetamol [acetaminophen]-induced gastrotoxicity:revealed by induced hyperacidity in combination with acute or chronic inflammation. *Inflammopharmacology*, **14**(3-4):150-4.
- Raghdad A. Abd Al-Jaleel., 2012. Use of turmeric (*Curcuma longa*) on the performance and some physiological traits on the broiler diets. *The Iraqi Journal of Veterinary Medicine*, **36**(1):51-57.
- Ranganathan V., Punniamurthy D., Ahamad B. and Kumar M.S., 2013. Hepatoprotective activity of *Indigofera aspalathoides* in chicken. *Agricultural Research Communication Centre, Thanjavur (TN)*.
- Reddy L.S.S. Vara Prasad, Tangavel A., Leela V., Raju K.V.S. Narayan., 2009. Antioxidant enzyme status in broilers:Role of dietary supplementation of tulasi (*Ocimum sanctum*) and selenium. *Tamilnadu J. Veterinary & Animal Sciences*, **5**(6):251-256.
- Rekhate D.H., Ukey S., Mangle L.N. and Deshmukh B.S., 2010. Effect of dietary supplementation of Shatavari (*Asparagus racemosus* wild) on haematological parameters of broilers. *Veterinary World*, **3**(6):280-281.
- Sahu R and Saxena J. 2014. *In-vitro* study of antioxidant activity of conventional and non-conventional species of *Curcuma*. *World Journal of Pharmacy and Pharmaceutical Sciences*. **3**(7):934:939.
- Said M, Khan BA, Akhtar N, Mohammad T, Rasul A, Hussain I, Khan H, Badshah A., 2012. The morphology, extractions, chemical constituents and uses of *Terminalia chebula*: A review. *J Med. Plants Res.*, **6**(33):4772-4775.
- Samudralwar D.L. and Garg A.N., 1996. Minor and trace elemental determination in the Indian herbal and other medicinal preparations. *Biol. Trace Elem. Res.*, **54**:113-121.
- Sanerkin N.G., 1971. Acute myocardial necrosis in paracetamol poisoning. *Br Med J.*, **3**: 478 (letter).
- Sapakal V.D., Shikalgar T.S., Ghadge R.V., Adnaik R.S., Naikwade N.S. and Magdum CS., 2008. *In Vivo* Screening of Antioxidant Profile: A Review, *Journal of Herbal Medicine and Toxicology*, **2**(2):1-8.
- Seal Tapan., 2011. Nutritional composition of wild edible fruits in Meghalaya state of India and their Ethnobotanical importance. *Res. J. Bot.*, **6**(2):58-67.
- Sethy K., Swain P., Behera K., Sahoo N., Agrawalla J., Khadanga S., Mahapatra M.R. and Parhi S.S., 2017. Effects of turmeric (*Curcuma longa*) supplementation on antioxidants and immunity of broiler birds. *J. Livestock Sci.*, **8**:103-106.
- Shafqatullah, Khurram M., Asadullah, Khaliqurrehman and Khan F.A., 2013. Comparative analyses of *Ocimum sanctum* stem and leaves for phytochemicals and inorganic constituents. *Middle-East J. Sci. Res.*, **13**(2):236-240.
- Sharma A., Makwana M. and Rathore H.S., 2008. Can

- herbal paracetamol combination drug prevent both liver and kidney disease? Results and possibilities. *Ethanobotanical Leaflets, USA*, **12**:286-298.
- Sharma V., Agrawal R.C. and Sonam P., 2013. Phytochemical screening and determination of antibacterial and antioxidant potential of *Glycyrrizza glabra* root extracts. *J. Environ. Res. Develop.*, **7**(4):1552-1558.
- Singh N., Singh J.P. and Rajput M.K.S., 2008. Hematological alterations in broiler chicks during different seasons supplemented with herbal formulations. *Veterinary World*, **1**(4):110-112.
- Singh E., Sharma S., Pareek A., Dwiwedi J., Yadav S. and Sharma S., 2011. Phytochemistry, traditional uses and cancer chemopreventive activity of Amla (*Phyllanthus emblica*): The Sustainer. *Journal of Applied Pharmaceutical Science*, **2**(1):176-183.
- Suhail M. and Ahmad I., 1995. In vivo effects of acetaminophen on rat RBC and role of vitamin E. *Indian J Exp Biol*, **33**:269-271.
- Sujatha V., Korde J.P., Rastogi S.K., Maini S., Ravikanth K. and Rekhe D.S., 2010. Amelioration of heat stress induced disturbances of the antioxidant defence system in broilers. *J. Vet. Med. Anim Health*, **2**(3):18-28.
- Steir A., Bize P., Schull Q., Zoll J., Singh F., Geny B., 2013. Avian erythrocytes have functional mitochondria, opening novel perspectives for birds as animal models in the study of ageing. *Frontier in Zoology*, **10**:33.
- Swan G., Naidoo V., Cuthbert R., Green R.E., Pain D.J. and Swarup D., 2006. Removing the threat of diclofenac to critically endangered Asian Vultures. *Public Library of Science Biology*, **4**:66.
- Will E.J. and Tomkins A.M., 1971. Acute myocardial necrosis in paracetamol poisoning. *Br Med J.*, **4**:430-431 (letter).

